

# 99

· HARLEY STREET ·



ACADEMY OF  
ADVANCED  
ENDODONTICS

To Dr XXXX – Via Email

12<sup>th</sup> Oct 2023

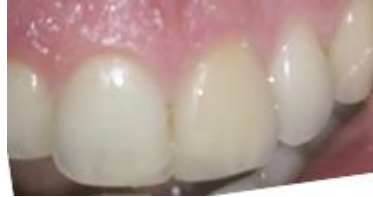Dear XXX

Re: Mr XXXXX.

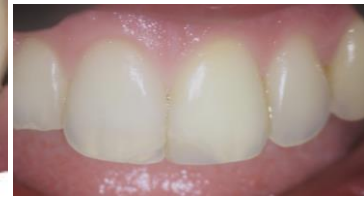Further to my email report, following endodontic treatment, of XXX's UL1, we have now completed internal bleaching and I have placed a permanent coronal seal using bonded GIC Nayyar style core.

The bleaching effect seems to have been quite successful and XXX was happy with the result. Once the colour has stabilised in 4-6 weeks, I would be grateful if you could either replace or reface the mesial composite edge.

Pre-Bleach



Post -Bleach



I will now review the combined orthograde and surgical treatment in 6 to 9 months and keep you updated with the result.

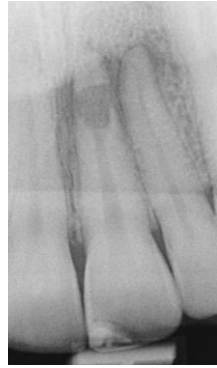
Many thanks again for this kind referral and the opportunity to work with you.

Best Wishes,

Richard S. Kahan  
Specialist Endodontist

Director, Academy of Advanced Endodontics

Pre-Op Xray



Post-Op Xray

